

Xanthogranulomatous Cholecystitis: CT and USG Characteristics

SIDDARTH RAGUPATHI¹, SAHADEVAN VIJAY²

ABSTRACT

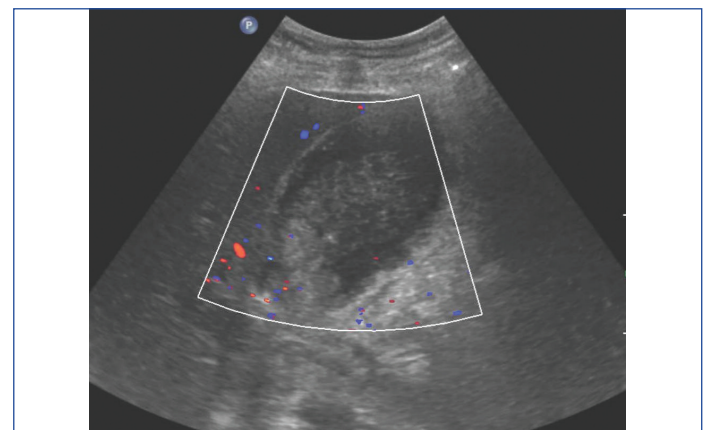
Cholecystitis is a common finding in everyday practice of ultrasound. The diagnosis of Xanthogranulomatous Cholecystitis (XGC) is however an uncommon entity and every radiologist should be aware of the characteristic ultrasound and CT findings to identify it. Here, we present a 68-year-old female with fever and abdominal pain showing the classic imaging features of a Xanthogranulomatous cholecystitis which was confirmed post cholecystectomy with histopathological diagnosis.

Keywords: Bands, Foam cells, Histiocytes

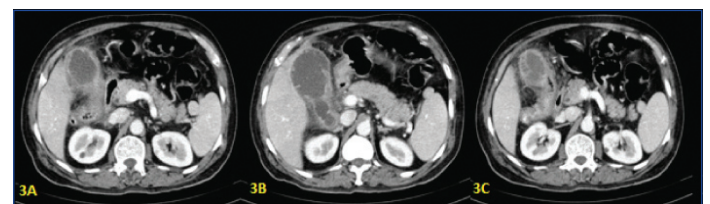
CASE REPORT

A 68-year-old female presented with three months history of low grade fever and chills associated with self limiting abdominal pain and vomiting for the past three weeks. There was a history of 5 kg weight loss in the past two months. On examination, there was a palpable, hard mobile mass in the epigastric region. Murphy's sign was negative. At first, Gastro Intestinal malignancy was suspected and so Upper GI scopy was performed which didn't make out any abnormality in the stomach. So, with the clinical diagnosis of suspected malignancy probably involving the pancreas, the patient has been referred to radiology for evaluation. Ultrasonography of the abdomen was done which showed thickened gallbladder and soft tissue echogenicity within the lumen associated with a calculus [Table/Fig-1,2]. The soft tissue echogenicity within the lumen was thought to be sludge. Pancreas was found to be normal. Differential diagnosis of chronic calculus cholecystitis and a possibility of malignancy were given and contrast enhanced CT scan was advised. CECT abdomen was done which confirmed the gallbladder wall thickening associated with the characteristic multiple hypodense areas along the wall. The fat plane with the adjacent surface of liver was maintained whereas the fat plane with transverse colon was lost or effaced. So, a radiological diagnosis of Xanthogranulomatous cholecystitis (XGC) was given [Table/Fig-3]. The patient was started on antibiotics and antipyretics until the fever subsided following which a preoperative diagnosis of either cholecystitis or carcinoma was made by the surgeons and open cholecystectomy was planned. On the operating table, the gallbladder lumen was found to be filled with pus with wall thickening and adhering to the adjacent part of the transverse colon. Successful removal of the gallbladder was done

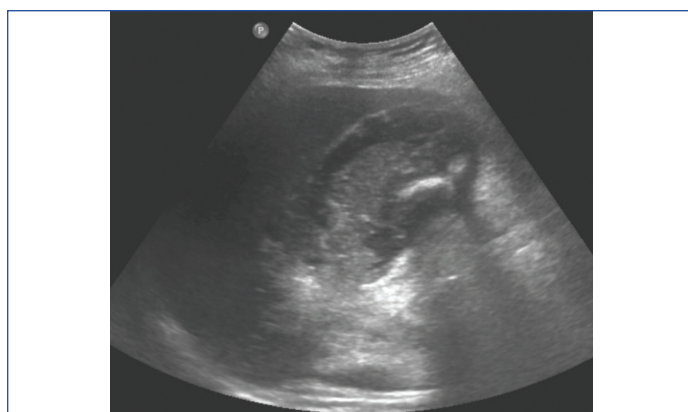
and the specimen was sent for histopathological examination. The pathologists confirmed the diagnosis of XGC with the presence of histiocytes, foam cells, multinucleate giant cells along with varying proportions of inflammatory cells.



[Table/Fig-2]: Ultrasound colour Doppler showing no internal vascularity within the echogenic part.



[Table/Fig-3]: A) CECT abdomen showing thickened gallbladder wall with significant pericholecystic fat stranding. B and C) CECT abdomen showing hypodense peripheral non-enhancing band-like areas noted along the wall of the gallbladder.



[Table/Fig-1]: Ultrasound showing irregularly thickened gallbladder wall with a soft tissue echogenicity within the lumen, associated with a calculus.

DISCUSSION

Xanthogranulomatous cholecystitis, the term coined by McCoy JJ et al., is a benign uncommon variant of chronic cholecystitis with accumulation of lipid laden macrophages and inflammatory cells intramural being the hallmark finding [1,2]. It was described as fibrogranulomatous inflammation and ceroid granulomas of the gallbladder by Christensen AH et al., and Amazon K et al., [3,4]. It occurs most commonly in the 6th and 7th decades of life with male predominance twice than the females [5]. There were also reported studies of male to female ratio of 1:9 in India [6]. The reason for such higher incidence rates in India has been proposed to be due to higher gallstone occurrence among the population [7,8]. There were also studies which reported Xanthogranulomatous cholecystitis more commonly in elderly females of 60-70 years of age [9,10].

The condition begins with biliary obstruction due to the gallstones or other less common causes, increasing the intraluminal pressure and bile stasis [11]. This causes extravasation of bile into the wall, with the Rokitansky-Aschoff sinuses involved or through a small mucosal ulceration which results in granulomatous reaction with formation of intramural nodules [10,12,13]. The disease can lead to GB perforation, formation of abscess, fistulous opening into duodenum resulting in air in the biliary tree and extensive inflammation involving adjacent abdominal viscera such as liver [14].

Even though radiological and biochemical studies were done, confirmatory diagnosis is made only at surgery or histopathological examination. The most common differential diagnosis to consider while evaluating is malignancy which was done in the present case. Several studies were done to correlate the surgical and histopathological diagnosis of XGC and the results were contradictory with some cases misdiagnosed as malignant pre and intraoperative findings which came out to be XGC on histopathology [15].

Gross specimen of XGC shows abnormal soft to firm gallbladder wall thickening with poorly demarcated intramural nodules appearing yellow-brown [16,17].

The investigation of choice is Ultrasonography which shows focal or diffuse wall gallbladder thickening with intramural hypoechoic bands or nodules which correlated with foam and inflammatory cells or necrosis and/or abscess and most often, the gallstones with CT confirming the findings. However, none of the findings described in literature are diagnostic and it may not be possible to differentiate XGC gallbladder wall thickening from carcinomatous wall thickening [18,19]. The use of contrast ultrasound was found to be more accurate in differentiating the two entities [20].

The most important differential diagnosis is gallbladder carcinoma which is indistinguishable by CT with the characteristic hypoattenuating nodules with wall thickening driving us to the diagnosis of XGC. A retrospective study by Goshima S et al., [21] proposed five CT findings to differentiate both these entities which includes: 1) Diffuse gallbladder wall thickening; 2) Continuous mucosal line; 3) Intramural hypoattenuated nodules; 4) Absence of macroscopic hepatic invasion; and 5) Absence of intrahepatic bile duct dilatation.

The use of MRI in diagnosing XGC is limited. There will be apparent diffusion restriction GB cancer with wall-thickening and the apparent diffusion coefficient value will be higher in XGC than in cancer [22].

However, there are past case reports with normal wall thickness which provides evidence that the CT findings may be more apparent in the acute phase of the disease, requiring histopathological support for the diagnosis [23]. Fine-needle aspiration biopsy has been used in several cases with good results [9,10]. Cholecystectomy, either laparoscopic or open, depending on the extent of the disease is the treatment of choice. However, open cholecystectomy is more preferred due to the presence of dense fibrosis and the possibility of co-existing malignancy which will be difficult to resect with laparoscopic approach.

CONCLUSION

In conclusion, Xanthogranulomatous cholecystitis is a benign granulomatous disease, an uncommon variant of chronic

cholecystitis. Ultrasound and CT findings of focal or diffuse gallbladder wall thickening with hypoattenuating intramural bands or nodules are the characteristic imaging findings, often associated with gallstones. Preoperative diagnosis of XGC is important in excluding malignancy and in the proper surgical management.

REFERENCES

- [1] McCoy JJ, Vila R, Petrossian G, McCall RA, Reddy KS. Xantho granulomatous cholecystitis. Report of two cases. *J S C Med Assoc.* 1976;72:7879 [PMID: 1063276]
- [2] Singh VP, Rajesh S, Bihari C, Desai SN, Pargewar SS, Arora A. Xanthogranulomatous cholecystitis: What every radiologist should know. *World J Radiol.* 2016;8(2):183-91. ISSN 1949-8470 (online)
- [3] Christensen AH, Ishak KG. Benign tumors and pseudotumors of the gallbladder. Report of 180 cases. *Arch Pathol.* 1970;90:42332 [PMID: 4319984]
- [4] Amazon K, Rywlin AM. Ceroid granulomas of the gallbladder. *Am J Clin Pathol.* 1980;73:12327 [PMID: 7352416]
- [5] Guzmán-Valdivia G. Xanthogranulomatous cholecystitis in laparoscopic surgery. *J Gastrointest Surg.* 2005;9:49497. [PMID: 15797229]
- [6] Balagué C, Targarona EM, Sugañes G, Rey MJ, Arce Y, Viella P, Trias M. Xanthogranulomatous cholecystitis simulating gallbladder neoplasm: therapeutic implications. *Gastroenterol Hepatol.* 1996;19:50306 [PMID: 9044748]
- [7] Ros PR, Goodman ZD. Xanthogranulomatous cholecystitis versus gallbladder carcinoma. *Radiology.* 1997;203:1012. [PMID: 9122374]
- [8] Krishna RP, Kumar A, Singh RK, Sikora S, Saxena R, Kapoor VK. Xanthogranulomatous inflammatory strictures of extrahepatic biliary tract: presentation and surgical management. *J Gastrointest Surg.* 2008;12:836-41.
- [9] Casas D, Pérez-Andrés R, Jiménez JA, Mariscal A, Cuadras P, Salas M, et al. Xanthogranulomatous cholecystitis: a radiological study of 12 cases and review of the literature. *Abdom Imaging.* 1996;21:456-60 [Google Scholar]
- [10] Kim PN, Ha HK, Kim YH, Lee MG, Kim MH, Auh YH, et al. US findings of xanthogranulomatous cholecystitis. *Clin Radiol.* 1998;53:290-92. [Google Scholar]
- [11] Suzuki H, Wada S, Araki K, Kubo N, Watanabe A, Tsukagoshi M, et al. Differential diagnosis of Xanthogranulomatous cholecystitis. *World J Gastroenterol.* 2015;21(35):10166-73. ISSN 1007-9327 (print) ISSN 2219-2840 (online)
- [12] Roberts KM, Parsons MA. Xanthogranulomatous cholecystitis: clinicopathological study of 13 cases. *J Clin Pathol.* 1987;40:412-17 [PMID: 3584484]
- [13] Goodman ZD, Ishak KG. Xanthogranulomatous cholecystitis. *Am J Surg Pathol.* 1981;5:653-59 [PMID: 7337158]
- [14] Lee KC, Yamazaki O, Horii K, Hamba H, Higaki I, Hirata S, et al. Mirizzi syndrome caused by xanthogranulomatous cholecystitis: report of a case. *Surg Today.* 1997;27:757-61. [PMID: 9306594]
- [15] Deng Y-L, Cheng N-S, Zhang S-J, Ma W-J, Shrestha A, Li F-Y, et al. Xanthogranulomatous cholecystitis mimicking gallbladder carcinoma: An analysis of 42 cases. *World J Gastroenterol.* 2015;21(44):12653-59.
- [16] Spinelli A, Schumacher G, Pascher A, Lopez-Hanninen E, Al-Abadi H, Benckert C, et al. Extended surgical resection for xanthogranulomatous cholecystitis mimicking advanced gallbladder carcinoma: A case report and review of literature. *World J Gastroenterol.* 2006;12:2293-96. [PMID: 16610041]
- [17] Yang T, Zhang BH, Zhang J, Zhang YJ, Jiang XQ, Wu MC. Surgical treatment of xanthogranulomatous cholecystitis: experience in 33 cases. *Hepatobiliary Pancreat Dis Int.* 2007;6:504-08. [PMID: 17897914]
- [18] Guzmán-Valdivia G. Xanthogranulomatous cholecystitis: 15 years' experience. *World J Surg.* 2004;28:254.
- [19] Chun KA, Ha HK, Yu ES, Shinn KS, Kim KW, Lee DH, et al. Xanthogranulomatous cholecystitis: CT features with emphasis on differentiation from gallbladder carcinoma. *Radiology.* 1997;203:93.
- [20] Yuan HX, Wang WP, Wen JX, Ji ZB, Ding H, Huang BJ, et al. Xanthogranulomatous cholecystitis: contrast-enhanced ultrasound features and differential diagnosis from wall-thickening gallbladder carcinoma. *Discov Med.* 2016;21:89.
- [21] Goshima S, Chang S, Wang JH, Kanematsu M, Bae KT, Federle MP, et al. Xanthogranulomatous cholecystitis: diagnostic performance of CT to differentiate from gallbladder cancer. *Eur J Radiol.* 2010;74:e79.
- [22] Zhao F, Lu PX, Yan SX, Wang GF, Yuan J, Zhang SZ, et al. CT and MR features of xanthogranulomatous cholecystitis: an analysis of consecutive 49 cases. *Eur J Radiol.* 2013;82:1391.
- [23] Chun KA, Ha HK, Yu ES, Shinn KS, Kim KW, Lee DH, et al. Xanthogranulomatous cholecystitis: CT features with emphasis on differentiation from gallbladder carcinoma. *Radiology.* 1997;203:93-97 [Medline] [Google Scholar]

PARTICULARS OF CONTRIBUTORS:

1. Assistant Professor, Department of Radiology, Vinayaka Mission Medical College, Vinayaka Mission Research Foundation, Karaikal, Pondicherry, India.
2. Assistant Professor, Department of Radiology, Christian Medical College Hospital, Vellore, Tamil Nadu, India.

NAME, ADDRESS, E-MAIL ID OF THE CORRESPONDING AUTHOR:

Dr. Sahadevan Vijay,
10/25, Banadurai South Street, Kumbakonam, Tamil Nadu, India.
E-mail: zephyrs87@yahoo.co.in

FINANCIAL OR OTHER COMPETING INTERESTS: None.

Date of Submission: **Oct 27, 2018**
Date of Peer Review: **Dec 12, 2018**
Date of Acceptance: **Jan 05, 2019**
Date of Publishing: **Apr 01, 2019**